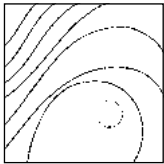


Bruxism Elicited by Inferior Alveolar Nerve Injury: A Case Report



Marcello Melis, DMD, RPharm*
Carlo Coiana, MD, DMD**
Simona Secci, MD**

The aim of this case report is to describe the history of a patient who received an injury to the right inferior alveolar nerve after placement of a dental implant, with bruxism noted afterward. The symptoms were managed by the use of an occlusal appliance worn at night and occasionally during the day, associated with increased awareness of parafunction during the day to reduce muscle pain and fatigue. Paresthesia of the teeth, gingiva, and lower lip persisted but were reduced during appliance use. (Int J Periodontics Restorative Dent 2012;32:e29–e33.)

Injury to the inferior alveolar nerve is a potential complication of the surgical placement of mandibular endosseous dental implants.¹⁻⁴ The prevalence of symptoms reported by patients depends on the site of implant placement, type of surgical procedures adopted, design of the studies, sensitivity of the testing methods, choice of the outcome measures, and terminology used to describe sensory disturbances.¹ The severity and duration of symptoms depends on the extent of the anatomical injury to the nerve. Such injuries are differentiated following the Seddon classification into three classes: neuropraxia, axonotmesis, and neurotmesis.⁴ Neuropraxia is the result of mild trauma caused by compression or tension to the nerve, without damage to the axonal pathway. It is usually associated with temporary disturbances of the nerve conduction. Axonotmesis is a more significant injury where the general structure of the nerve remains intact but some axons may be interrupted, and edema, ischemia, and demyelination may occur. Disturbances of nerve conduction

*Private Practice, Cagliari, Italy; Adjunct Clinical Instructor, Craniofacial Pain Center, Tufts University, School of Dental Medicine, Boston, Massachusetts.

**Private Practice, Cagliari, Italy.

Correspondence to: Dr Marcello Melis, Via Grosseto 1, 09125 Cagliari, Italy;
fax: (+39) 070-497293; email: marcellomelis01@libero.it.

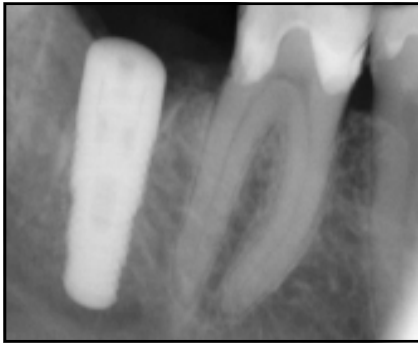
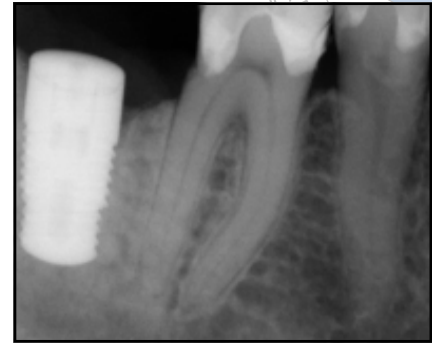


Fig 1 (left) Radiograph taken after placement of the first dental implant.

Fig 2 (right) Radiograph taken after replacement of the first dental implant with a shorter implant.



may be permanent. Neurotmesis involves disruption of the nerve and nerve sheath, with consequent interruption of nerve conduction. Sensory recovery is not possible without microneurosurgical intervention.⁴

Usually, spontaneous complete recovery from neuropraxia symptoms occurs in approximately 4 weeks without intervention. For axonotmesis, symptoms slowly improve from 5 to 11 weeks after the injury to the next 10 to 12 months; paresthesia (abnormal sensation, whether spontaneous or evoked, that is not described as unpleasant),^{5,6} hypoesthesia (diminished sensitivity to stimulation),⁵ and dysesthesia (unpleasant abnormal sensation, whether spontaneous or evoked)^{5,6} may persist. Microneurosurgical reconstruction is appropriate in cases of persistent pain or dysesthesia.⁴ Neurotmesis is characterized by an interruption of the axons and the nerve sheath. Therefore, micro-

neurosurgical intervention is necessary to reestablish proper alignment of the nerve stumps to promote correct regeneration.⁴ However, prognosis of normal sensory recovery is poor.⁴

Bruxism is defined as a diurnal or nocturnal parafunctional activity including clenching, bracing, gnashing, and grinding of the teeth.⁷ It is considered a phenomenon mainly originating in the central nervous system, sometimes affected by emotional and psychologic factors; however, peripheral factors can play a role.⁸

The following report describes a patient who developed bruxism after inferior alveolar nerve injury.

Case report

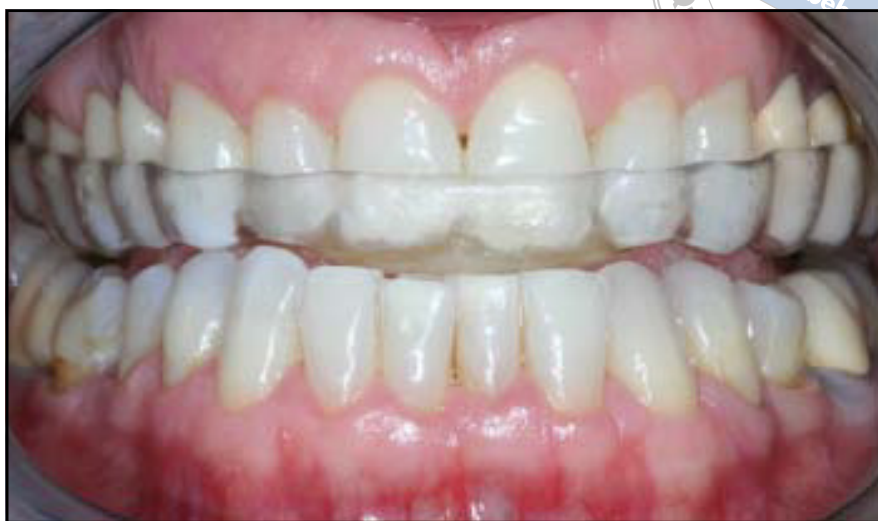A 45-year-old Caucasian woman presented to the authors' dental office for evaluation. Her chief complaint was altered touch sensation of the right mandibular teeth and

gingiva and numbness of the skin on the right side of the chin associated with clenching of the teeth with heavy contact on the right side. Pain and fatigue in the masseter muscles were also present. The symptoms developed after a surgical procedure for insertion of a dental implant in the site of the mandibular right second molar 1 year earlier. Following the first surgical intervention, the implant was removed and replaced by a second implant, which was shorter than the previous one, to eliminate compression of the nerve (Figs 1 and 2).

The patient said that the reduced sensation of touch between the teeth on the right side made her try to feel the "normal" sensation by clenching hard on that side. Clenching provided partial immediate relief, but then exacerbated the symptoms. When the teeth were kept apart, discomfort was minimal.

During clinical examination, the patient showed moderate pain

Fig 3 Maxillary occlusal appliance with tooth contacts limited to the mandibular incisors.



on palpation of the masseter muscles, no temporomandibular joint pain or dysfunction, and no evident signs of dental wear. No alteration of the soft tissues (tongue, alveolar mucosa, cheek) was present. Touch sensation was altered on the mandibular teeth and gingiva on the right side from the first molar to the incisors. Also, the right side of the chin showed paresthesia and hypoesthesia. The tongue was not involved. Sensory testing of the skin and mucosa was performed using a cotton swab for sensation of touch and a pin for pain, stimulating the affected side and comparing it to the contralateral side. Assessment of tooth sensation was performed by tooth percussion and asking the patient to clench on a cotton roll.

Symptoms were likely to be a result of trauma to the right inferior alveolar nerve that occurred during the surgical procedure and placement of the dental implant. In fact, the symptoms were localized to the

territory of the nerve, distal to the first molar, including the mental nerve. Trauma resulting from local anesthesia to the inferior alveolar nerve would also have involved the sensibility of the lingual nerve, which originates distal to the site of the injection, and symptoms would have involved the tongue.^{2,9}

Hypoesthesia and paresthesia had significantly reduced from the time of the surgery, becoming stable over the last couple of months. According to the anamnesis and clinical evaluation (sensory testing), the injury described by the patient fell within the class of axonotmesis. Quantitative sensory testing was not performed because after 1 year from the nerve injury, it was considered irrelevant for the treatment and prognosis of the disease. Surgical intervention was not suggested since there was no pain or dysesthesia, and favorable recovery can occur only if nerve repair is performed within 4 to 6 months

from the time of injury.^{2,4}

The use of a maxillary occlusal appliance was suggested to palliate the effects of bruxism, reducing excessive tooth contact on the affected side. It was made to be worn during the night (the patient reported the symptoms to be more intense when waking up in the morning) and during the day when appropriate. Contacts of the mandibular teeth with the appliance were limited to the four incisors (Fig 3). Such a choice was made because avoiding contacts between the posterior teeth was hypothesized to reduce the generation of clenching forces by the elevator muscles and because the purpose was to avoid tooth contact on the right side during clenching.¹⁰ In addition, mandibular incisors are usually innervated by the ipsilateral inferior alveolar nerve and partially by the contralateral inferior alveolar nerve; therefore, the altered sensation reported by the patient was likely to

be reduced in those sites.^{11,12} This was confirmed clinically. The patient was also asked to try to limit diurnal parafunctions and to pay more attention to such occurrences.

After 1 week, the patient reported marked reduction of discomfort upon waking in the morning and use of the appliance during the daytime when she had the tendency to clench the teeth. Reduction of tooth contact on the affected side during clenching eliminated the peaks of discomfort that used to occur after intense parafunctional activity; however, mild hypoesthesia and pares-thesia persisted. The patient was reminded to limit use of the appliance during the day to avoid the risk of extrusion of the posterior teeth, which were not in contact when the appliance was worn. At 1, 6, and 10 months of follow-up, the patient was still wearing the appliance at night and occasionally during the day; the symptoms remained unchanged.

Discussion

To the authors' knowledge, this is the first case reported in the literature of bruxism elicited by injury to the inferior alveolar nerve. According to the patient's report, the altered sensation of the contact on the mandibular teeth on the right side forced her to clench the teeth, attempting to feel a "normal" touch sensation. Such activity caused initial partial relief because it changed the sensation on the teeth, but then the discomfort increased. Another hypothesis is that

suppression of the proprioception in the periodontal ligaments on the right side resulting from the injury to the right inferior alveolar nerve caused inequality of the sensation to the teeth between the left and right side. This could have been the trigger for parafunction in an attempt to equalize the sensations coming from the injured and uninjured sides of the dental arch.

Since the symptoms were minimal at rest, the authors tried to palliate the effect of bruxism by avoiding contact between the teeth. The design of the appliance was decided with the purpose of allowing contacts with the mandibular incisors only. Such an appliance must be used with caution because of the risk of extrusion of the posterior teeth that are not in contact when it is worn. The risk is minimal when the use of the appliance is restricted to the night, but can be significant if it is extended to the day as well, especially for long periods. However, the decision to choose that design was made, together with the patient, to avoid tooth contact on the right side. The patient was informed of the possible side effect and taught to limit the use of the appliance during the day and to periodically check and notice any modification on tooth contact. The approach was successful, eliminating the peaks of discomfort caused by parafunction, while, as expected, hypoesthesia and pares-thesia persisted, although causing only mild discomfort to the patient.

The effect of the appliance could also be related to the con-

temporary suppression of tooth proprioception coming from the left and right sides, equalizing the sensations coming from the teeth.

Even though the feeling described by the patient that the altered sensation on the teeth was the reason for increased tooth clenching is reasonable, the authors cannot exclude the notion that bruxism was already present and that the discomfort was more evident because of the nerve injury. In the latter case, nerve trauma would not be the cause of the parafunction but would contribute to the symptoms. However, the treatment proposed would still be appropriate. If the hypothesis that paresthesia and hypoesthesia of the teeth can elicit bruxism is true, this would suggest that peripheral factors can play a role in the genesis of bruxism in specific cases.

Conclusions

Although bruxism seems to be a phenomenon mainly originating in the central nervous system, peripheral factors can play a role. In the present case report, altered sensation on the mandibular teeth resulting from inferior alveolar nerve injury represented a possible trigger. The outcome of the present case report must not be overestimated because of the limitations of the description of only one patient. However, evaluation of bruxism can be suggested in patients who receive injury to the alveolar nerve.

References

1. Dao TT, Mellor A. Sensory disturbances associated with implant surgery. *Int J Prosthodont* 1998;11:462–469.
2. Kraut RA, Chahal O. Management of patients with trigeminal nerve injuries after mandibular implant placement. *J Am Dent Assoc* 2002;133:1351–1354.
3. Worthington P. Injury to the inferior alveolar nerve during implant placement: A formula for protection of the patient and clinician. *Int J Oral Maxillofac Implants* 2004;19:731–734.
4. Hegedus F, Diecidue RJ. Trigeminal nerve injuries after mandibular implant placement—Practical knowledge for clinicians. *Int J Oral Maxillofac Implants* 2006; 21:111–116.
5. Okeson JP. Terminology. In: Okeson JP (ed). *Bell's Orofacial Pains*, ed 5. Chicago: Quintessence, 1995:xvii–xx.
6. Backonja MM, Galer BS. Pain assessment and evaluation of patients who have neuropathic pain. *Neurol Clin* 1998;16: 775–790.
7. Okeson JP. *Orofacial Pain: Guidelines for Assessment, Diagnosis, and Management*. Chicago: Quintessence, 1996:230.
8. Lobbezoo F, Naeije M. Bruxism is mainly regulated centrally, not peripherally. *J Oral Rehabil* 2001;28:1085–1091.
9. Pogrel MA, Thamby S. Permanent nerve involvement resulting from inferior alveolar nerve blocks. *J Am Dent Assoc* 2000;131:901–907.
10. Shankland WE 2nd. Migraine and tension-type headache reduction through pericranial muscular suppression: A preliminary report. *Cranio* 2001;19:269–278.
11. Yonchak T, Reader A, Beck M, Meyers WJ. Anesthetic efficacy of unilateral and bilateral inferior alveolar nerve blocks to determine cross innervation in anterior teeth. *Oral Surg Oral Med Oral Pathol Oral Radiol Endod* 2001;92:132–135.
12. Blanton PL, Jeske AH. The key to profound local anesthesia: Neuroanatomy. *J Am Dent Assoc* 2003;134:753–760.