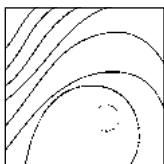




Alveolar Ridge Reconstruction with a Composite Alloplastic Biomaterial



David M. Kim, DDS, DMSc¹/Marcelo Camelo, DDS²
 Myron Nevins, DDS³/Ardavan Fateh, DDS⁴
 Peter Schupbach, PhD⁵/Marc Nevins, DMD, MMSc⁶

The purpose of this case report was to analyze the outcome of alveolar ridge reconstruction procedures with composite alloplastic biomaterial (biphasic calcium phosphate composed of 30% hydroxyapatite and 70% β -tricalcium phosphate) for the treatment of large alveolar ridge defects. The clinical and histologic findings demonstrated that this alloplastic biomaterial can be used to potentially regenerate large alveolar ridge defects. This composite biomaterial appears to be safe, biocompatible, and osteoconductive. (Int J Periodontics Restorative Dent 2012;32:e204–e209.)

¹Assistant Professor, Division of Periodontology, Department of Oral Medicine, Infection and Immunity, Harvard School of Dental Medicine, Boston, Massachusetts, USA.

²Institute for Advanced Dental Studies, Belo Horizonte, Brazil.

³Associate Clinical Professor, Division of Periodontology, Department of Oral Medicine, Infection and Immunity, Harvard School of Dental Medicine, Boston, Massachusetts, USA.

⁴Research Fellow, Division of Periodontology, Department of Oral Medicine, Infection and Immunity, Harvard School of Dental Medicine, Boston, Massachusetts, USA.

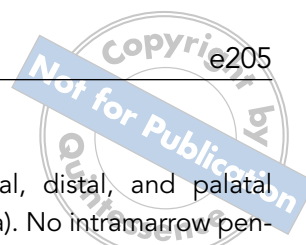
⁵Schupbach Ltd, Service and Research Laboratory for Biomaterials, Histology, and Imaging, Horgen, Switzerland.

⁶Assistant Clinical Professor, Division of Periodontology, Department of Oral Medicine, Infection and Immunity, Harvard School of Dental Medicine, Boston, Massachusetts, USA.

Correspondence to: Dr David M. Kim, Harvard School of Dental Medicine, 188 Longwood Avenue, Boston, MA 02115; fax: 617-432-1897; email: dkim@hsdm.harvard.edu.

Alveolar ridge reconstruction is an important but challenging procedure used to correct deformities resulting from advanced periodontal disease, traumatic tooth extraction, maxillofacial trauma, and tumor resection. Inappropriate diagnosis and treatment frequently result in critical-size alveolar ridge defects filled with fibrous connective tissues rather than vital bone.¹

The basic tenant of osseointegration is that the implant is housed in alveolar bone. Clinicians have used various surgical techniques with a variety of bone graft substitutes in block or particulate forms to resolve large alveolar ridge defects. However, the extent and morphology of the defects are unique and may dictate or limit the use of currently available biomaterials. Autogenous bone harvested from either extra- or intraoral sites is still considered to be the gold standard, but allogenic, xenogenic, and alloplastic materials have become more accepted because of inherent complications related to autogenous bone harvesting and patient preference.



Alloplastic materials such as hydroxyapatite (HA) and β -tricalcium phosphate (β -TCP) are promising because of their synthetic nature and their ability to facilitate new bone formation. A bone replacement graft should act as a scaffold for new bone formation and subsequently allow remodeling of the newly formed bone. The combination of both HA and β -TCP has been used successfully in socket preservation, alveolar ridge augmentation, and sinus augmentation procedures.²⁻⁶ A randomized, multicenter, prospective clinical trial demonstrated that there was no difference in the amount of newly formed bone between biphasic calcium phosphate (60% HA and 40% β -TCP) and anorganic bovine bone when used as sinus augmentation materials.³

A new alloplastic bone substitute combining 30% HA and 70% β -TCP is now available in the form of both blocks and particulates. The granules are 70% porous with interconnected pores of 250 μ m (Osteon 2, Dentium). The advantage of combining an insoluble HA with a resorbable β -TCP is that the slow-resorbing HA will maintain the volume while faster-resorbing β -TCP will promote bone regeneration. The biocompatibility and osteoconductivity of this graft formulation were demonstrated previously in clinical studies.⁷⁻⁹

The aim of this case report was to analyze the outcome of alveolar ridge reconstruction procedures with composite alloplastic biomaterial (biphasic calcium phosphate

composed of 30% HA and 70% β -TCP; Osteon 2) for the treatment of large alveolar ridge defects.

Method and materials

Two healthy patients without significant medical conditions agreed to undergo alveolar ridge augmentation with this composite alloplastic biomaterial. They were enrolled in an implant retrieval study, which required removal of a nonstrategic implant and reconstruction of the biopsy sites with bone graft. All dental treatments were provided free of cost. Both patients signed an informed consent form based on the Helsinki Declaration of 1975, as revised in 2000, and understood that they had the choice of withdrawing from the procedure at any time.

The implant retrieval procedure was performed on an outpatient basis. Both patients received multiple implants, and a total of three dental implants (one implant from the first patient and two implants from the second patient) were removed from the maxilla. The biopsy site was anesthetized with local anesthetics (2% xylocaine with 1:100,000 epinephrine), and the implant biopsies with adjacent tissue were accomplished utilizing piezoelectric surgery (Piezosurgery, Piezosurgery). Removal of a small conservative rectangular block was performed to preserve as much alveolar bone as possible (Figs 1a and 2a). The block retrieval sites presented with three-wall defects

(intact mesial, distal, and palatal walls) (Fig 2a). No intramarrow penetration of the recipient site was necessary. A composite alloplastic biomaterial (Osteon 2) was passively packed into the recipient site without any fixation or tenting screws (Figs 1b and 2b). A barrier membrane (Collagen Membrane, Dentium) was placed over the grafted site for two biopsy sites, while the third site did not receive a barrier membrane. Periosteal releasing incisions were completed to achieve tension-free flap closure, and interrupted and mattress sutures (expanded polytetrafluoroethylene, W.L. Gore) were used to achieve passive primary flap closure.

Sutures were removed at 2 weeks, and patients were seen on a monthly basis thereafter to assess healing. A dental computed tomography (CT) scan was obtained 6 months after alveolar ridge reconstruction to determine the gain in bone volume, and the reconstructed sites were reentered to assess healing. A 2-mm-diameter trephine bur (Dentium) was used to obtain a bone core within the augmented region to assess the bone quality. The trephine burs were immediately placed in formalin and processed for histologic and histomorphometric analyses.

Light microscopy

Histologic processing was performed on three biopsy specimens. The cores were embedded

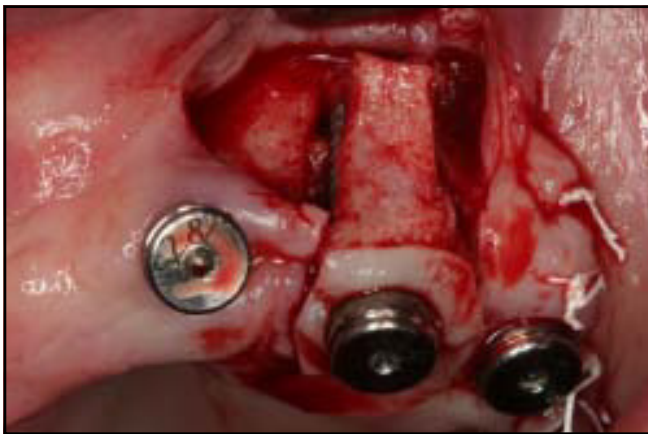


Fig 1a Small conservative rectangular-shaped block removal was performed at the biopsy site utilizing piezoelectric surgery. The specimen presented with three-wall defects.

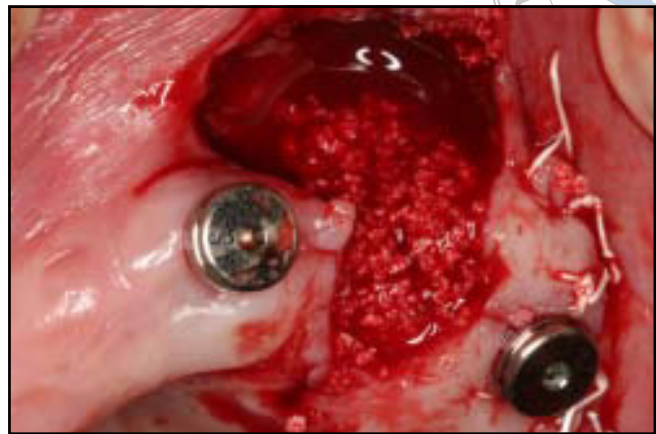


Fig 1b Composite alloplastic biomaterial (Osteon 2) passively packed into the recipient site without any fixation or tenting screws. A barrier membrane was placed over the grafted site.

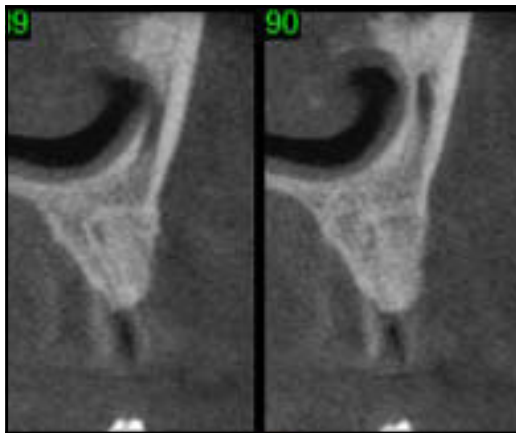


Fig 1c CT scan at 6 months demonstrating radiopacity resembling reconstruction of the ridge at the biopsy site.

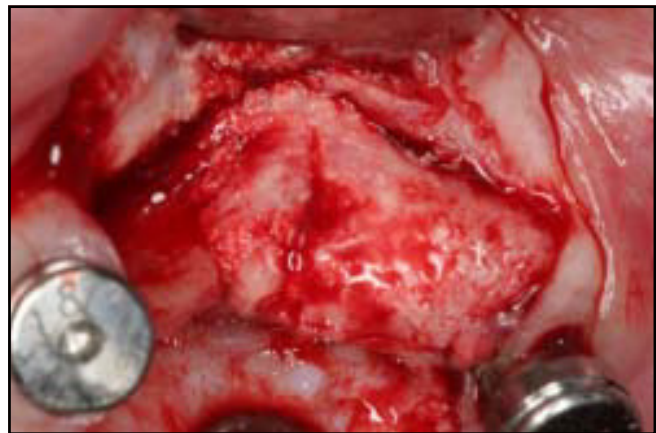

Fig 1d Clinical reentry at 6 months gave the impression of a well-restored ridge contour.

following complete dehydration in ascending grades of ethanol in a light-curing one-component composite resin (Technovit 7200 VLC, Heraeus Kulzer). Polymerized blocks were initially ground to bring the tissue components closer to the cutting surface. A 100- μm -thick section attached to the second slide was sectioned with a diamond blade and 50 to 100 g of pressure. The final thickness of 40 μm was achieved by

grinding and a final polishing using 1,200-, 2,400-, and 4,000-grit sandpaper. Sections from each block were used for staining with Sanderson's rapid bone stain. Light microscopic overview images of the cores were taken digitally using a Leica M16 stereomicroscope (Leica Microsystems). The percentages of new bone, bone marrow, and graft particles were analyzed using computer software (Image-Access, Imagic).

Results

Clinical and radiographic findings

No adverse events or complications such as membrane or biomaterial exposure, infection, or wound dehiscence were observed during the healing period. The CT scan evaluation 6 months after the procedure demonstrated the possibility of radiographic reconstruction of the

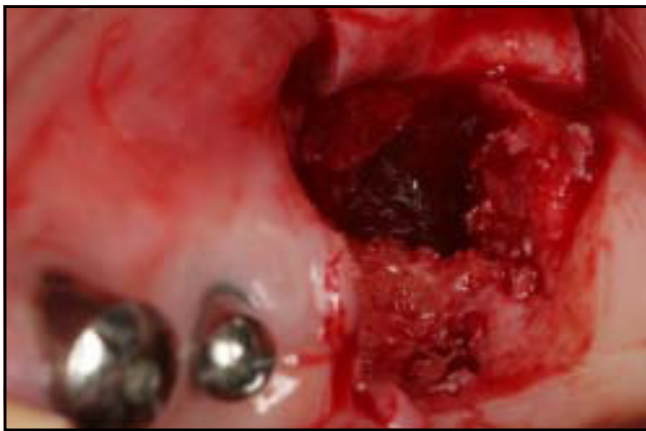

Fig 2a A second small conservative rectangular-shaped block removal was performed utilizing piezoelectric surgery at the biopsy site. The specimen presented with three-wall defects.

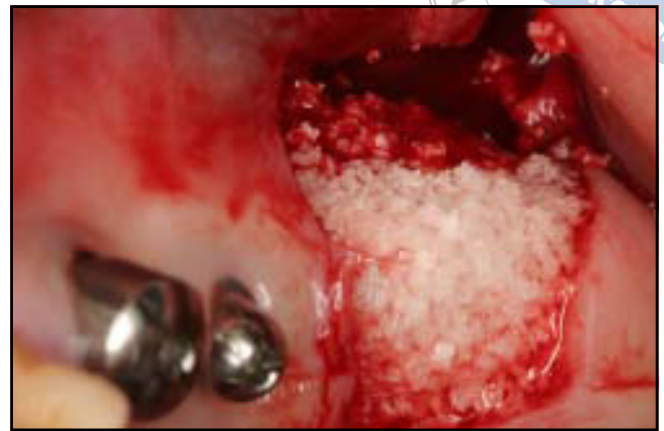

Fig 2b Composite alloplastic biomaterial (Osteon 2) passively packed into the recipient site without barrier membrane placement.

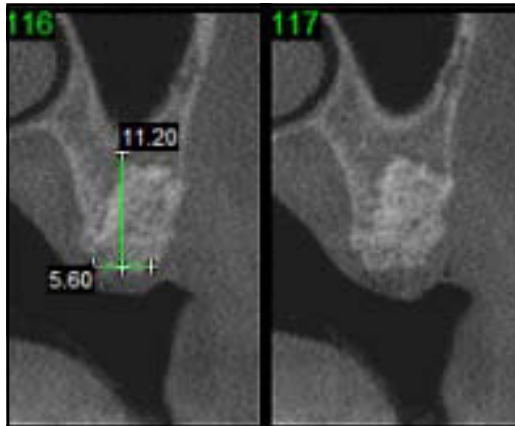


Fig 2c CT scan evaluation at 6 months demonstrating the possibility of radiographic reconstruction of the ridge at the biopsy site.

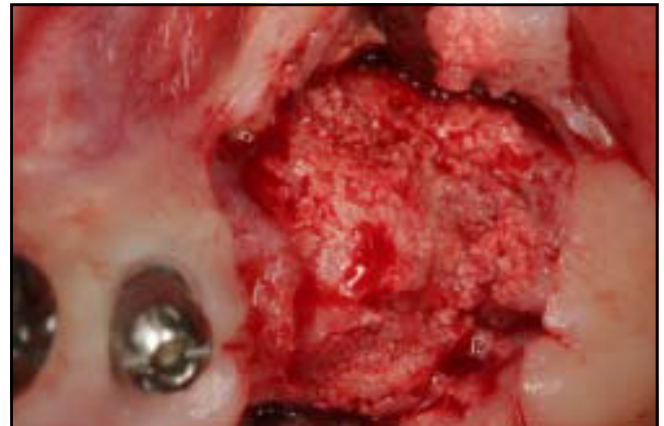

Fig 2d Clinical reentry at 6 months revealed well-incorporated biomaterials in the surrounding native bone.

ridge at the biopsy site (Figs 1c and 2c). Surgical exposure of the augmentation site revealed biomaterials that were incorporated into the surrounding native bone (Figs 1d and 2d). None of the augmented sites exhibited fibrous soft tissue in-growth between the graft and recipient site. Significant regeneration of the reconstructed ridge contour was observed from all three sites, and the regenerated areas seemed to be stable and resistant

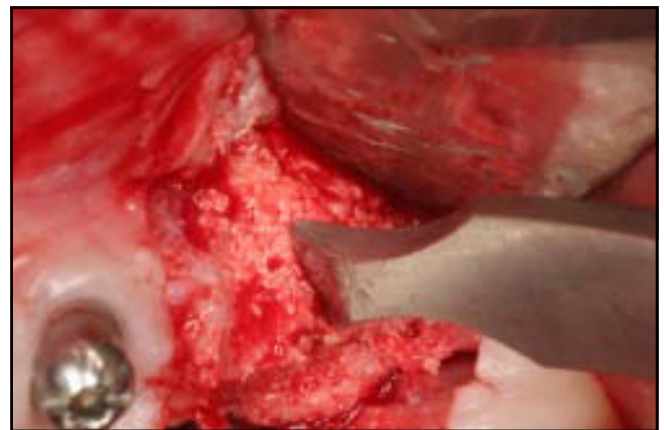


Fig 2e The regenerated site resisted instrumentation.

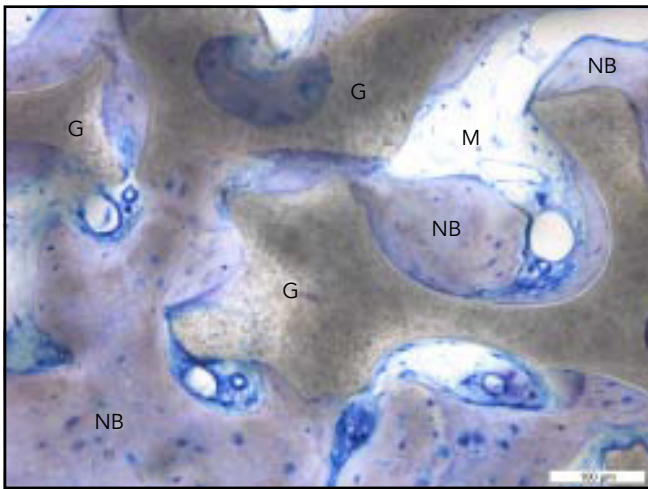


Fig 3a Histologic examination of the bone biopsy specimen obtained in Fig 2 showing graft particles (G) surrounded by newly formed woven bone (NB) and marrow space (M). New bone bridging the space between the graft particles was noted.

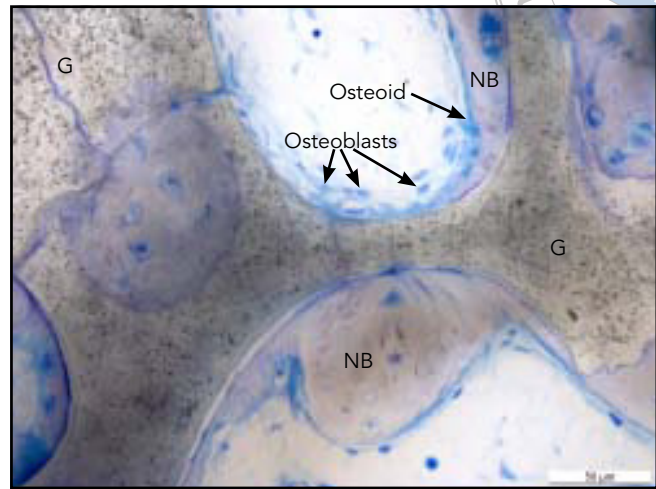


Fig 3b The specimen showed ongoing bone formation (NB) along the graft surface (G) by osteoblasts lining the osteoid.

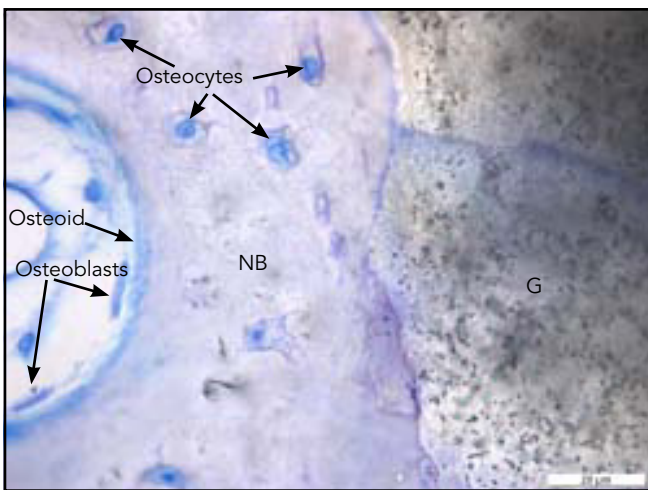


Fig 3c Intimate contact between a graft particle (G) and newly formed bone (NB) was noted. Ongoing bone formation was evidenced by the presence of osteoblasts and osteoid. Also, osteocytes were being incorporated into newly formed bone.

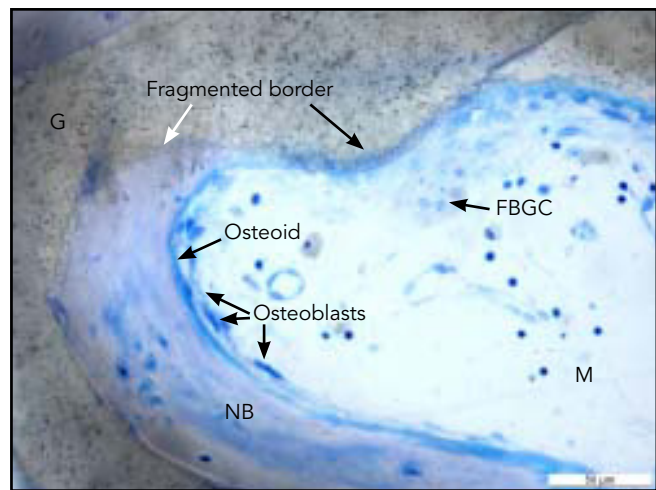


Fig 3d Fragmentation of the graft border (G) by a multinucleated foreign body giant cell (FBGC). Note the ongoing osteoconductive bone formation (NB) along the graft border resulting in the incorporation of the previously fragmented graft border in newly formed bone (white arrow). M = marrow.

even after the trephine biopsy procedure (Fig 2e). The site that did not receive membrane coverage appeared to have the best regenerative outcome.

Histologic findings

Histologic examination revealed an absence of inflammatory cells and bone formation in all grafted

sites along with the presence of biomaterial particles and connective tissue (Figs 3a to 3d). Newly formed woven bone was observed throughout the entire length of the

bone cores. The grafted biomaterial was distinguished from the native and new bone using staining. Graft particles were incompletely resorbed but well integrated and in complete continuity with the new bone tissue. The formation of new bone on the surface of the biomaterial particles and bridging the space between the biomaterial particles was noted (Fig 3a). Ongoing new bone formation along the graft particle surface by osteoblasts lining the osteoid was observed (Figs 3b and 3c). Fragmentation of the remaining graft border by a multinucleated foreign body giant cell was also observed (Fig 3d). Histomorphometric analysis of the cores revealed an average of 32.1% vital bone (range, 31.2% to 32.7%) and 33.1% remaining graft particles (range, 17.8% to 42.5%).

Discussion

An autogenous bone block graft, which possesses sufficient strength and rigidity to allow fixation of the recipient site, was previously considered to be the best treatment option for large alveolar ridge defects because of its three-dimensional stability. Particulate bone grafts have not been considered previously for large alveolar ridge reconstructions since they do not possess the structural stability of the block graft. The development of an effective reconstruction protocol without autogenous block grafts will be of significant benefit to the patient.

The clinical and histologic findings from this study demonstrated that an alloplastic particulate biomaterial composed of HA and β -TCP can be used successfully for treating large alveolar ridge defects. This composite biomaterial appears to be safe and biocompatible and demonstrated good osteoconductivity. The advantages of the described technique include elimination of the block graft and fixation screws. The particulate biomaterial allows intimate contact between the biomaterial and defect, which is not easily accomplished by the block.

Conclusions

The results indicate that a composite alloplastic biomaterial composed of HA and β -TCP can promote new bone formation via osteoconduction to augment localized ridge defects. Further studies are needed to determine the predictability of this technique and better understand the long-term clinical and biologic outcomes of this biomaterial when used to support dental implants with and without a barrier membrane.

Acknowledgment

This study was funded by a grant from Dentium.

References

1. Bosch C, Melsen B, Vargervik K. Importance of the critical-size bone defect in testing bone-regenerating materials. *J Craniofac Surg* 1998;9:310-316.
2. Cordaro L, Bosshardt DD, Palattella P, Rao W, Serino G, Chiapasco M. Maxillary sinus grafting with Bio-Oss or Straumann Bone Ceramic: Histomorphometric results from a randomized controlled multicenter clinical trial. *Clin Oral Implants Res* 2008; 19:796-803.
3. Froum SJ, Wallace SS, Cho SC, Elian N, Tarnow DP. Histomorphometric comparison of a biphasic bone ceramic to anorganic bovine bone for sinus augmentation: 6- to 8-month postsurgical assessment of vital bone formation. A pilot study. *Int J Periodontics Restorative Dent* 2008; 28:273-281.
4. Frenken JW, Bouwman WF, Bravenboer N, Zijdeveld SA, Schulten EA, ten Bruggenkate CM. The use of Straumann Bone Ceramic in a maxillary sinus floor elevation procedure: A clinical, radiological, histological and histomorphometric evaluation with a 6-month healing period. *Clin Oral Implants Res* 2010;21:201-208.
5. Mardas N, Chadha V, Donos N. Alveolar ridge preservation with guided bone regeneration and a synthetic bone substitute or a bovine-derived xenograft: A randomized, controlled clinical trial. *Clin Oral Implants Res* 2010;21:688-698.
6. Mardas N, D'Aiuto F, Mezzomo L, Arzoumanidi M, Donos N. Radiographic alveolar bone changes following ridge preservation with two different biomaterials. *Clin Oral Implants Res* 2011;22: 416-423.
7. Kim YK, Yun PY, Lim SC, Kim SG, Lee HJ, Ong JL. Clinical evaluations of OSTEON as a new alloplastic material in sinus bone grafting and its effect on bone healing. *J Biomed Mater Res B Appl Biomater* 2008;86:270-277.
8. Kim YK, Yun PY, Kim SG, Lim SC. Analysis of the healing process in sinus bone grafting using various grafting materials. *Oral Surg Oral Med Oral Pathol Oral Radiol Endod* 2009;107:204-211.
9. Bae JH, Kim YK, Kim SG, Yun PY, Kim JS. Sinus bone graft using new alloplastic bone graft material (Osteon)-II: Clinical evaluation. *Oral Surg Oral Med Oral Pathol Oral Radiol Endod* 2010;109: e14-e20.