


Analysis of Soft Tissue Display During Enjoyment Smiling: Part 1—Caucasians



Xiulian Hu, DMD¹/Susanne Nahles, DDS²
 Carolyn A. Nelson, BS³/Ye Lin, MD⁴/
 Katja Nelson, DDS, PhD⁵

Esthetic considerations have become increasingly important in dental therapy. Evaluation of the soft tissue display during enjoyment smiling can provide useful information for esthetic oral rehabilitation. To date, no study has quantified the amount and frequency of soft tissue display in the area of the papilla. Photographic examination of 66 fully dentate patients with a mean age of 28.5 years was performed during enjoyment smiling. Digital processing and measurement of the tooth, gingival, and papillary display revealed that over 90% of subjects displayed papillae in the anterior teeth and first premolars during enjoyment smiling regardless of sex. The frequency of display in descending order consisted of maxillary lateral incisors (96%), central incisors (94%), canines (94%), first premolars (91%), second premolars (85%), and first molars (39%). The mean papillary display was 3.4 mm (range, 0.0 to 10.0 mm). There was no significant difference in the amount of papillary display between the sexes for anterior teeth, premolars, or first molars (P = .97, P = .79, and P = .48, respectively). (Int J Periodontics Restorative Dent 2013;33:e9–e15. doi: 10.11607/prd.0882)

¹Associate Professor, Department of Implant Dentistry, Peking University, School and Hospital of Stomatology, Beijing, China; Research Scientist, Implantology and Special Prosthodontics, Clinic and Policlinic for Oral and Maxillofacial Surgery, Charité Campus Virchow Clinic, Berlin, Germany.

²Assistant Professor, Implantology and Special Prosthodontics, Clinic and Policlinic for Oral and Maxillofacial Surgery, Charité Campus Virchow Clinic, Berlin, Germany.

³Intern, Clinic and Policlinic for Oral and Maxillofacial Surgery, Charité Campus Virchow Clinic, Berlin, Germany.

⁴Professor and Head, Department of Implant Dentistry, Peking University, School and Hospital of Stomatology, Beijing, China.

⁵Professor, Clinic for Oral and Maxillofacial Surgery, University Clinic Freiburg, Freiburg, Germany.

Correspondence to: Professor Katja Nelson, Clinic for Oral and Maxillofacial Surgery, University Clinic Freiburg, Hugstetter Str. 55, 79100 Freiburg, Germany; fax: +49 30 4505 55901; email: katja.nelson@uniklinik-freiburg.de

©2013 by Quintessence Publishing Co Inc.

Esthetics has become increasingly important in the practice of modern dentistry. Many patients seek dental care because of a desire to look more attractive by improving their smiles.^{1–8} An attractive smile enhances the acceptance of an individual in modern society by improving initial impressions in interpersonal relationships.^{1,2} There are two basic types of smiles: the social smile and the enjoyment smile.^{4,2} During a social smile, the teeth are displayed to a moderate degree and the gingiva is sometimes visible. During an enjoyment smile (maximal contraction of the perioral muscles), maximal tooth and gingival display is achieved.^{4,5}

Smile analysis provides information about the relationship of the teeth with their surrounding soft tissues. These are key elements for diagnosis and treatment planning in esthetic dentistry.^{1–10} The esthetic area is defined as the area that is visible during a patient's full smile, and an esthetic implant restoration is one that resembles a natural appearance in all aspects.^{11,12} Soft tissue parameters are used to measure the esthetic outcome of an implant-retained

restoration. Among these are the midfacial mucosal implant margin in relation to the incisal edge as well as the position of the tip of the papilla.¹³ Esthetic considerations of the soft tissue contour in implant-retained restorations have mainly focused on single-tooth implants.^{10,11,14-16} Several studies have shown that esthetics is an important factor for complete denture success.¹⁷⁻¹⁹ Focus has been placed on restoring function and comfort in edentulous patients, and esthetics has been limited to the ideal position of the denture teeth.²⁰ Few reports have focused on the importance of restoring the soft tissue contour in edentulous patients using artificial materials.²¹⁻²³ The perception of dental esthetics varies among dental professionals. Therefore, guidelines have been promoted to achieve common standards. The mathematic quantification of natural parameters facilitates the establishment of these guidelines; therefore, esthetic-related soft tissue parameters taken from dentate patients may provide information for the esthetic fabrication of implant-retained restorations in edentulous arches.

Studies concerning smile analysis have been mainly performed from an orthodontic perspective.^{1-7,24} The majority of these studies comprised the evaluation of the anterior region during social smiling^{1,4,6-9}; few studies have evaluated gingival and tooth display during enjoyment smiling in males,^{2,3} and only two studies evaluated this parameter in males and females.^{24,25} No data are available on the

amount and frequency of papillary display during smiling even though the papilla is seen as a critical factor in achieving the appropriate soft tissue symmetry and harmony around a prosthetic restoration.¹⁴

The aim of this study was to obtain information on the amount and frequency of the displayed soft tissue profile, including the papilla, during enjoyment smiling.

Method and materials

Sixty-six subjects (30 men, 36 women; mean age, 28.4 years; range, 20 to 35 years) were selected from a Caucasian population of European origin with no facial disharmonies. They were enrolled and photographed only if they had complete natural maxillary dentitions without periodontal disease, caries, or prosthodontic treatment. The research proposal was approved by the Ethics Committee of the Charité University Medicine, Berlin, Germany, and informed consent was obtained from each participant.

Recording and measurement

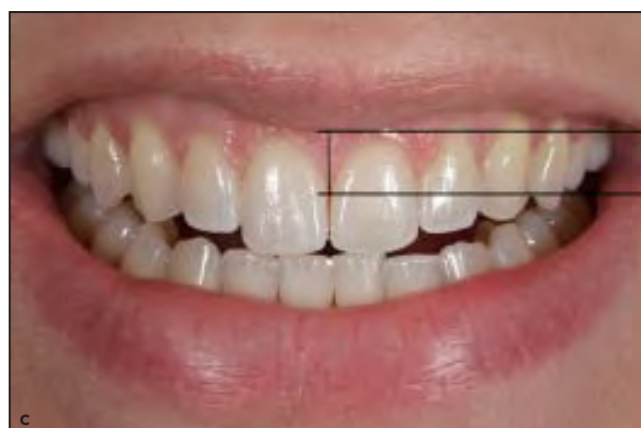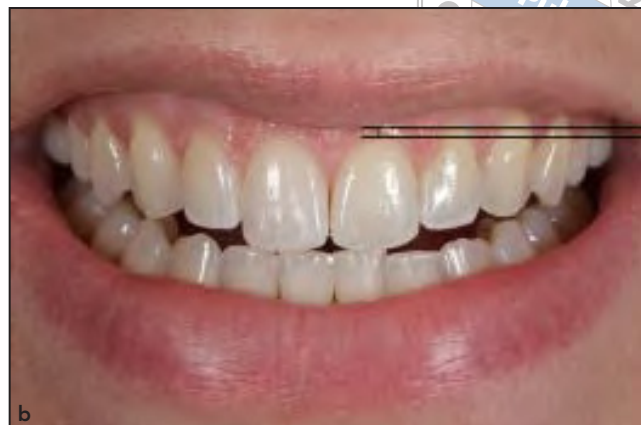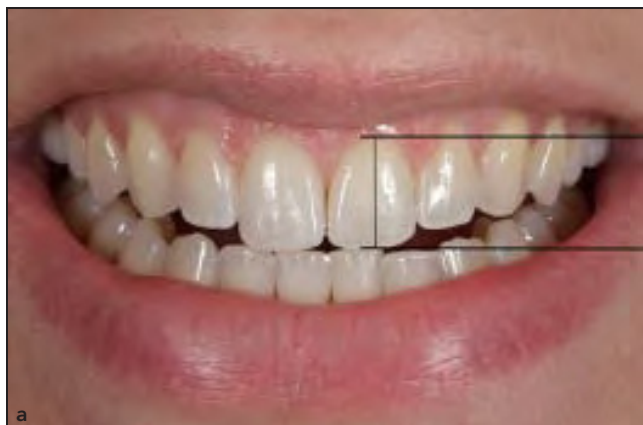A digital camera (EOS D20, Canon) was placed on a tripod, and the lens (60 mm, Macro-Objective, Canon) was adjusted to be parallel to the occlusal plane. The shutter speed was 1/125 second and the aperture was f/9.5. Subjects were instructed to hold their heads naturally by looking forward and were induced to laugh. A leveled

ruler fixed on a tripod was placed near each subject's face as a reference standard to enable calibration in the digital measurement. In all subjects, the clinical crown length of the maxillary central incisors was measured using a digital caliper and compared with the digital measurement to guarantee the reliability of this method. The image best displaying the maximum enjoyment smile in each patient was selected for evaluation. Each image was processed in Photoshop CS4 (Adobe) and measured three times.

Each tooth displayed in the maxilla during enjoyment smiling was measured to exclude influences of facial asymmetry. The following parameters were measured (Figs 1a to 1c). Height of tooth display was measured from the incisal or occlusal inferior edge of the tooth to the most inferior edge of the upper lip when the tooth was not fully displayed. If the entire tooth was displayed, the distance from the zenith to the incisal edge was measured. The height of the gingival display was defined as the distance from the zenith to the most inferior edge of the upper lip. The height of papillary display was measured from the tip of the papilla to the most inferior edge of the upper lip. If the tooth, gingiva, or papilla was not visible, the data were defined as zero.

Statistical analysis

Descriptive analysis was performed with all data recorded. The Mann-Whitney *U* test (SPSS 13, IBM) and



Figs 1a to 1c Parameters measured: (a) visible tooth display, (b) visible gingival display, and (c) visible papillary display during enjoyment smiling.

two-factorial analysis for repeated measures (SAS 9.1, SAS Institute) were used for statistical analysis. Significance was defined as $P < .05$.

Results

Tooth display

All subjects displayed portions of their maxillary teeth up to the first premolar, and over 90% showed their second premolar during enjoyment smiling. The mean length of tooth display was 9.4 mm (range, 3.5 to 13 mm) for the central incisor, 8.5 mm (range, 3.9 to 12.6 mm) for the lateral incisor, 9.0 mm (range, 1.5 to 15.7 mm)

for the canine, 7.2 mm (range, 3.7 to 9.7 mm) for the first premolar, 5.7 mm (0.0 to 9.2 mm) for the second premolar, and 2.3 mm (range, 0.0 to 8.5 mm) for the first molar. Men displayed more tooth height (mean, 7.2 mm) at all maxillary teeth than women (mean, 6.8 mm) except for at the first molar, but a significant difference was only found for anterior teeth ($P = .01$). No significant variation in the amount of display of the premolars and first molars was found between sexes ($P = .71$ and $P = .28$, respectively). Forty-two percent of subjects showed the entire length of their central incisor, 65% displayed the entire lateral incisor, 50% showed the entire canine,

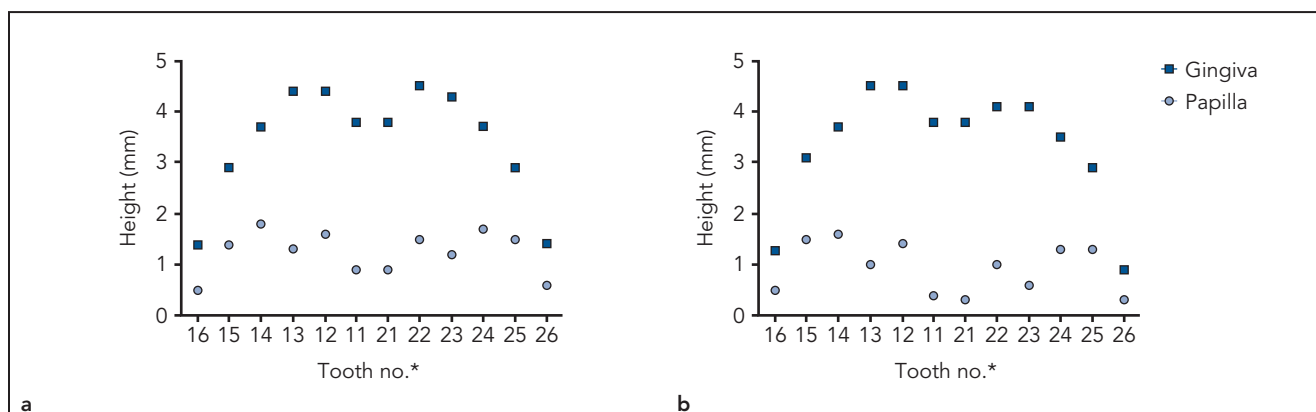
50% showed the entire first premolar, 41% showed the entire second premolar, and 24% showed the entire first molar.

Gingival display

The mean gingival display was 1.3 mm (range, 0.0 to 6.4 mm). The frequency of gingival display is provided in Table 1. The greatest mean gingival display was found at the first and second premolars, followed by the canine, lateral incisor, and central incisor in descending order. The mean gingival display was lowest in the region of the first molar (mean, 0.5 mm; range, 0.0 to 4.0 mm). Seventeen percent of

Table 1 Frequency of gingival display (%)

	Central incisor	Lateral incisor	Canine	First premolar	Second premolar	First molar
Women (n = 36)	42	58	47	53	49	26
Men (n = 30)	28	58	40	62	60	22



Figs 2a and 2b Mean values of gingival and papillary display during enjoyment smiling for (a) women and (b) men. * FDI tooth-numbering system.

subjects displayed gingiva from the central incisor to the first molar. The mean gingival height of such subjects was 2.7 mm (range, 0.7 to 6.4 mm).

The mean gingival display in women was 1.5 mm (range, 0.0 to 6.4 mm). Figure 2 depicts the mean gingival display itemized by region and gender. Twenty-two percent of women displayed gingiva from the central incisor to the first molar, with a mean of 3.0 mm (range, 0.7 to 6.4 mm). Men had a mean gingival display of 1.1 mm (range, 0.0 to 4.8 mm). The greatest mean gingival display was found at the first and second premolars (Fig 2b).

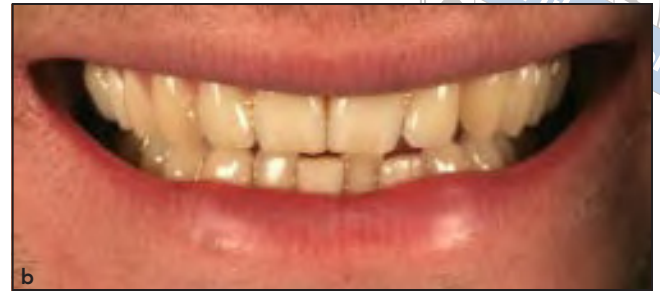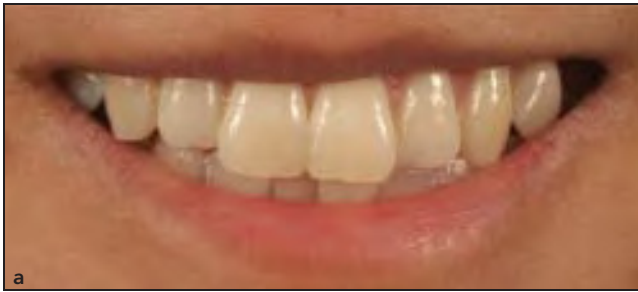Ten percent of men displayed gingiva from the central incisor to the first molar. The mean gingival display for these subjects was 2.5 mm (range, 0.7 to 4.8 mm). Twenty percent of the subjects did not display any gingiva during enjoyment smile (Fig 3).

Women showed slightly more gingiva than men, but this difference was not significant in either the anterior teeth, premolars, or first molars ($P = .43$, $P = .8$, and $P = .57$, respectively). Sixty-two percent of subjects displayed gingiva during enjoyment smiling in the region of at least one of the teeth evaluated.

Papillary display

Overall, subjects showed a mean papilla height of 3.4 mm (range, 0.0 to 10.0 mm). Mean papillary display was 3.8 mm (range, 0.0 to 9.3 mm) at the central incisor, 4.4 mm (range, 0.0 to 10.0 mm) at the lateral incisor, 4.3 mm (range, 0.0 to 9.9 mm) at the canine, 3.7 mm (range, 0.0 to 9.1 mm) at the first premolar, 3.0 mm (range, 0.0 to 8.6 mm) at the second premolar, and 1.3 mm (range, 0.0 to 7.2 mm) at the first molar.

The papillae of the anterior teeth and the first premolar were displayed in over 90% of subjects.



Figs 3a to 3d Clinical photographs of subjects who did not display gingiva during enjoyment smiling but presented soft tissue in the area of the papilla.

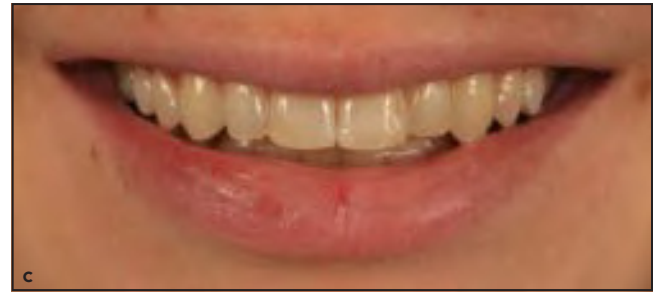

Table 2 Frequency of papillary display (%)

	Central incisor	Lateral incisor	Canine	First premolar	Second premolar	First molar
Women (n = 36)	94	97	94	92	83	43
Men (n = 30)	93	95	93	90	87	35

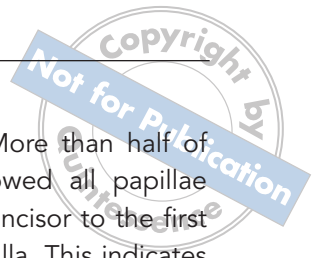
The frequency of papillary display in each region is shown in Table 2. Fifty-three percent of subjects showed papillae from the central incisor to the first molar, with a mean papillary height of 3.4 mm (range, 0.5 to 9.0 mm). In women, the mean display was 3.4 mm (range, 0.0 to 10.0 mm). The lateral incisor and canine presented the greatest mean papillary display, followed by the first and second premolars (Figs 2a and 2b).

Fifty-six percent of women showed papillae from the central incisor to the first molar. The mean display was 3.5 mm (range, 0.5 to 9.0 mm) (Fig 2a). In men, the

mean papillary display was 3.3 mm (range, 0.0 to 8.2 mm) (Fig 2b). Fifty percent of men displayed papillae from the central incisor to the first molar, with a mean of 3.4 mm (range, 0.5 to 8.1 mm). Women tended to show a greater amount and frequency of papillary display than men, but without a significant difference for the anterior teeth, premolars, and first molars ($P = .97$, $P = .79$, and $P = .48$, respectively). If the molar was displayed during smiling, the papilla was also displayed.

Discussion

Over 90% of subjects, regardless of sex, displayed soft tissue during enjoyment smiling. The existing literature has mainly focused on the display of gingiva in the anterior teeth and premolars.^{2,3,8,24,25} Even though the papilla is seen as a critical factor in the reestablishment of natural crown ratios and a natural soft tissue profile,^{5,14} no quantification of the display of soft tissue in the area of the papilla during enjoyment smiling has been performed to date.



In this study, the display of maxillary teeth (central incisor to first molar) during enjoyment smiling was measured. The results show that men display significantly more clinical crown length at the anterior maxillary teeth than women. This is in accordance with the findings of Al-Habahbeh et al.²⁵ Kapagiannidis et al²⁴ did not quantify tooth display during enjoyment smiling, only the frequency of tooth display. Peck et al⁸ measured the clinical crown length of the maxillary left central incisor but not the amount of tooth display during smiling.

Kapagiannidis et al²⁴ evaluated the maxillary left central incisor, canine, and premolars of subjects with a broad age range of 16 to 82 years. The mean values of all subjects were analyzed statistically and revealed that females display their teeth more frequently than males, but the difference was only significant for the central incisors. Forty-two percent of central incisors were noted as displaying the entire clinical crown, similar to the results of this study. This study revealed that the entire maxillary lateral incisor is most frequently displayed in both sexes, followed by the first premolar. More than 20% of subjects displayed their entire first molar. This indicates the necessity for esthetic evaluation of the maxillary premolars and first molar during restorative treatment.

The mean gingival display during enjoyment smiling found in women and men is in accordance with data found in other studies.^{24,25} Van der Geld et al^{2,3} reported the same mean gingival

display at the central incisors of Caucasian men as in this study. The maxillary second premolar showed the greatest mean gingival display during enjoyment smiling, which is in accordance with previous studies.^{2,3,24} The overall frequency of gingival display was slightly greater in this study when compared to the data presented by Kapagiannidis et al²⁴ and Al-Habahbeh et al.²⁵ This might be because those studies did not exclude subjects with periodontal disease. Also, patients with a broad age range were included, limiting the comparability with this study, which had a defined age range.

The interdental papilla is a critical factor in esthetic dentistry and remains a challenge for clinicians despite numerous techniques that have been described for its preservation and reformation.^{10,26-30} It has been postulated that the papilla enhances a youthful appearance and serves as a complimentary factor in age interpretation.^{14,31} However, no data on the amount and frequency of papillary display during smiling are available. Kapagiannidis et al²⁴ concluded that the overall amount of gingival display would increase if the values of the interdental papilla were included, but no data were reported. In this study, up to 97% of subjects displayed papillae in one or more maxillary sites during enjoyment smiling. Women displayed papillae more often than men but without statistical significance. More than 90% of anterior teeth and premolars displayed papillae during smiling, and half of the subjects showed the papilla of

the first molar. More than half of the subjects showed all papillae from the central incisor to the first molar in the maxilla. This indicates that the papilla is an important esthetic feature during dynamic oral function (eg, enjoyment smiling). In this study, only subjects between the ages of 20 and 35 years were measured. Therefore, age-related changes in the amount and frequency of gingival and papillary display cannot be addressed, necessitating further studies that evaluate age-dependent variations of soft tissue papillary display.

In clinical practice, enjoyment smile analysis can provide essential diagnostic information and quantify dynamic lip-tooth-gingiva relationships for the esthetic restoration of patients, including edentulous patients.

Conclusions

Restoration of the maxillary papilla can be crucial for an esthetic outcome. Up to 97% of subjects in this study displayed soft tissue in the area of the papilla of the lateral incisor during enjoyment smiling. Overall, papillary display in the anterior teeth and first premolar was exhibited in over 90% of subjects. The papilla of the second premolar was revealed in over 80% of subjects, whereas the papilla of the first molar was displayed in more than 30% of the subjects. There was no significant difference between the sexes.

Acknowledgments

Xiulian Hu was the recipient of a scholarship grant from the Camlog Foundation, Basel, Switzerland. The authors reported no conflicts of interest related to this study.

References

1. Tjan AH, Miller GD, The JG. Some esthetic factors in a smile. *J Prosthet Dent* 1984;51:24–28.
2. Van der Geld P, Oosterveld P, Kuijpers-Jagtman AM. Age-related changes of the dental aesthetic zone at rest and during spontaneous smiling and speech. *Eur J Orthod* 2008;30:366–373.
3. Van der Geld PA, Oosterveld P, van Waas MA, Kuijpers-Jagtman AM. Digital videographic measurement of tooth display and lip position in smiling and speech: Reliability and clinical application. *Am J Orthod Dentofacial Orthop* 2007;131:301.e1–301.e8.
4. Ackerman MB, Ackerman JL. Smile analysis and design in the digital era. *J Clin Orthod* 2002;36:221–236.
5. Ekman P, Davidson RJ, Friesen WV. The Duchenne smile: Emotional expression and brain physiology. II. *J Pers Soc Psychol* 1990;58:342–353.
6. Dong JK, Jin TH, Cho HW, Oh SC. The esthetics of the smile: A review of some recent studies. *Int J Prosthodont* 1999;12:9–19.
7. Sarver DM, Ackerman MB. Dynamic smile visualization and quantification: Part 1. Evolution of the concept and dynamic records for smile capture. *Am J Orthod Dentofacial Orthop* 2003;124:4–12.
8. Peck S, Peck L, Kataja M. The gingival smile line. *Angle Orthod* 1992;62:91–100.
9. Hulsey CM. An esthetic evaluation of lip-teeth relationships present in the smile. *Am J Orthod* 1970;57:132–144.
10. Garber DA, Salama MA. The aesthetic smile: Diagnosis and treatment. *Periodontol* 2000 1996;11:18–28.
11. Belser UC, Schmid B, Higginbottom F, Buser D. Outcome analysis of implant restorations located in the anterior maxilla: A review of the recent literature. *Int J Oral Maxillofac Implants* 2004;19(suppl):30–42.
12. Higginbottom F, Belser U, Jones JD, Keith SE. Prosthetic management of implants in the esthetic zone. *Int J Oral Maxillofac Implants* 2004;19(suppl):62–72.
13. Belser U, Buser D, Higginbottom F. Consensus statements and recommended clinical procedures regarding esthetics in implant dentistry. *Int J Oral Maxillofac Implants* 2004;19(suppl):73–74.
14. LaVacca MI, Tarnow DP, Cisneros GJ. Interdental papilla length and the perception of aesthetics. *Pract Proced Aesthet Dent* 2005;17:405–412.
15. Albino JE, Tedesco LA, Conny DJ. Patient perceptions of dental-facial esthetics: Shared concerns in orthodontics and prosthodontics. *J Prosthet Dent* 1984;52:9–13.
16. Chu SJ, Tarnow DP, Tan JH, Stappert CF. Papilla proportions in the maxillary anterior dentition. *Int J Periodontics Restorative Dent* 2009;29:385–393.
17. Brewer A. Selection of denture teeth for esthetics and function. *J Prosthet Dent* 1970;23:368–373.
18. Hirsch B, Levin B, Tiber N. Effects of patient involvement and esthetic preference on denture acceptance. *J Prosthet Dent* 1972;28:127–132.
19. Vallittu PK, Vallittu AS, Lassila VP. Dental aesthetics—A survey of attitudes in different groups of patients. *J Dent* 1996;24:335–338.
20. Waliszewski M, Shor A, Brudvik J, Rairgrodski AJ. A survey of edentulous patient preference among different denture esthetic concepts. *J Esthet Restor Dent* 2006;18:352–368.
21. Holst S, Blatz MB, Bergler M, Wichmann M, Eitner S. Implant-supported prosthetic treatment in cases with hard- and soft-tissue defects. *Quintessence Int* 2005;36:671–678.
22. Nelson K, Hildebrand D, Mehrhof J. Fabrication of a fixed retrievable implant-supported prosthesis based on electroforming: A technical report. *J Prosthodont* 2008;17:591–595.
23. Lixin X, Hu X, Mehrhof J, Nelson K. Clinical evaluation of a fixed (retrievable) implant-supported prosthesis in the edentulous jaw: A 5-year report. *Quintessence Int* 2010;41:277–283.
24. Kapagiannidis D, Kontonasaki E, Bikos P, Koidis P. Teeth and gingival display in the premolar area during smiling in relation to gender and age. *J Oral Rehabil* 2005;32:830–837.
25. Al-Hababah R, Al-Shammout R, Al-Jabrah O, Al-Omari F. Die auswirkungen des geschlechts auf die sichtbarkeit von zähnen und zahnfleisch im frontzahnbereich in ruhestellung und beim lächeln. *Eur J Esthet Dent* 2009;4:408–422.
26. Tarnow DP, Eskow RN, Zamzok J. Aesthetics and implant dentistry. *Periodontol* 2000 1996;11:85–94.
27. Jemt T. Regeneration of gingival papillae after single-implant treatment. *Int J Periodontics Restorative Dent* 1997;17:326–333.
28. Nordland WP, Sandhu HS. Microsurgical technique for augmentation of the interdental papilla: Three case reports. *Int J Periodontics Restorative Dent* 2008;28:543–549.
29. Reddy MS. Achieving gingival esthetics. *J Am Dent Assoc* 2003;134:295–304.
30. Fürhauser R, Florescu D, Benesch T, Haas R, Mailath G, Watzek G. Evaluation of soft tissue around single-tooth implant crowns: The pink esthetic score. *Clin Oral Implants Res* 2005;16:639–644.
31. Lombardi RE. The principles of visual perception and their clinical application to denture esthetics. *J Prosthet Dent* 1973;29:358–382.